Check for updates

Case Report

SAGE Open Medical Case Reports

SAGE Open Medical Case Reports
Volume 12: 1–6
© The Author(s) 2024
Article reuse guidelines:
sagepub.com/journals-permissions
DOI: 10.1177/2050313X241261157
journals.sagepub.com/home/sco
Sage

Acute myocardial infarction following "dry scooping" of a pre-workout supplement in a healthy young man of African origin: A case report

Pedro Pallangyo[1,2], Smita V Bhalia[2], Makrina Komba[1], Zabella S Mkojera[1], Eva S Manji[3], Jalack Millinga[4], Yona Gandye[2] and Peter R Kisenge[2]

Abstract

Dry scooping, a rather risky act of consuming undiluted pre-workout protein powder hoping for a more pronounced energy surge, is increasingly becoming a fitness trend worldwide. A previously healthy 25-year-old man of African origin presented with acute onset of crushing mid-sternal chest pain for 4 h. His symptoms began about an hour following completion of his 2-h exercise regimen at the gym. He had an unremarkable past medical history except for an 8-month consumption of a pre-workout supplement as part of his gym routine. He claimed to have adhered to the manufacturer's recommended method of using the supplement, except for 3 days prior to presentation when he started "dry scooping" following the viewing of a video advocating such practice from his fitness WhatsApp group. Cardiac evaluation revealed features in keeping with diagnosis of anterolateral ST-elevation myocardial infarction. Emergency coronary angiography revealed a thrombotic lesion completely occluding the proximal left anterior descending coronary artery with TIMI 0 flow distally. After successful balloon angioplasty, a drug-eluting stent was implanted successfully, restoring TIMI 3 flow to the proximal left anterior descending coronary artery. This case report aims to raise awareness among both clinicians and the general public regarding the pervasiveness of pre-workout supplements, improper methods of consumption, and the potential life-threatening repercussions of misuse.

Keywords

Acute myocardial infarction, acute coronary syndrome, coronary artery thrombosis, STEMI, pre-workout supplement, fitness supplements

Date received: 27 March 2024; accepted: 24 May 2024

Introduction

There is compelling and unequivocal epidemiologic evidence regarding the pivotal role of regular physical activity in preventing several chronic diseases, as well as in reducing the risk of premature death.[1–4] Despite such overwhelming evidence, over a third of individuals globally do not meet the World Health Organization recommended levels of physical activity.[5,6] Nevertheless, exercise-related medical and physiological complications, particularly sudden death, arguably remain a concern regarding the safety of physical activity.[7] For instance, sudden cardiac death is the most frequent cause of death among athletes across all ages, occurring almost threefold compared to nonathletes.[8–10] However, it is postulated that regular physical activity can reduce mortality by up to 50% in the general population.[4]

[1]Department of Research and Training, Jakaya Kikwete Cardiac Institute, Dar es Salaam, Tanzania
[2]Department of Cardiology, Jakaya Kikwete Cardiac Institute, Dar es Salaam, Tanzania
[3]Department of Clinical Support Services, Jakaya Kikwete Cardiac Institute, Dar es Salaam, Tanzania
[4]Department of Nursing, Jakaya Kikwete Cardiac Institute, Dar es Salaam, Tanzania

Corresponding Author:
Pedro Pallangyo, Jakaya Kikwete Cardiac Institute, P.O. Box 65141, Muhimbili, Dar es Salaam, Tanzania.
Email: pedro.pallangyo@gmail.com

Creative Commons Non Commercial CC BY-NC: This article is distributed under the terms of the Creative Commons Attribution-NonCommercial 4.0 License (https://creativecommons.org/licenses/by-nc/4.0/) which permits non-commercial use, reproduction and distribution of the work without further permission provided the original work is attributed as specified on the SAGE and Open Access pages (https://us.sagepub.com/en-us/nam/open-access-at-sage).

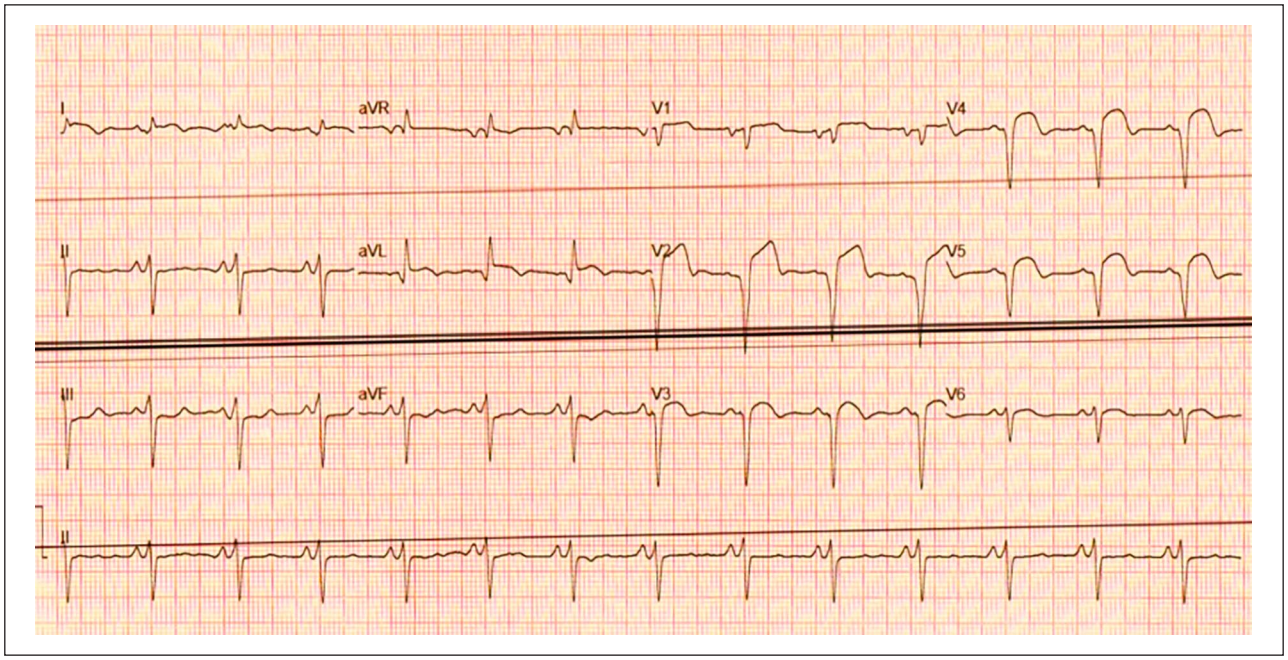

Figure 1. Electrocardiogram displaying sinus rhythm with marked ST elevation on the anterolateral leads (V2–V5, I, aVL) and reciprocal changes in the inferior leads (III and aVF).

Owing to its synergistic potential in improving mental focus, exercise capacity (i.e., delaying fatigue and increasing performance), and augmenting training adaptations,[11,12] pre-workout supplementation is estimated to be used by a considerable proportion of young adults globally.[13,14] However, consumption of these supplements has been linked with numerous negative health effects, including psychosis,[15] extensive esophageal ulcerations,[16] aplastic anemia,[17] hemorrhagic stroke,[18] ischemic colitis,[19] pancreatitis,[20] hepatic failure,[21] aortic dissection,[22] myocardial infarction,[23] cardiac arrest,[24] and death.[25] Moreover, despite their widespread popularity and increasing use, the exact composition of such products is often unknown, making their safety and efficacy profiles paradoxical.[12,26] We present a case of acute myocardial infarction following the practice of "dry scooping" a pre-workout supplement in a healthy young male of African origin.

Case description

A previously healthy 25-year-old man of African origin presented to the Jakaya Kikwete Cardiac Institute with an acute onset of crushing mid-sternal chest pain for 4 h. His symptoms had begun about an hour following completion of his regular (2 h/day, 5 times a week) exercise regimen (weightlifting and aerobics) at the gym. He had an unremarkable medical history, denied any history of recreational drug use or relevant occupational exposure, and did not experience symptoms associated with atherosclerosis at a younger age. Additionally, there was no family history of familial hypercholesterolemia, premature coronary artery disease, or sudden death. However, as part of his gym routine, he has been taking a pre-workout supplement (containing caffeine, theophylline, glucuronolactone, L-glycine, methylcobalamin, beta-alanine, CreNitrate, ArgNitrate, choline bitartrate, L-glutamine nitrate, L-tyrosine, guarana extract, and taurine) roughly 30 min before exercise for the past 8 months. He denied the use of alcohol, tobacco, or energy drink consumption. He claimed to have adhered to the manufacturer's recommended method of using the pre-workout supplement (i.e., mixing the protein powder with water or plant-based milk) all the way except for the past 3 days when he started "dry scooping" following the viewing of a video advocating such practice from his fitness WhatsApp group. Nevertheless, he claims that he has been adhering to an off-label recommendation of two single-serving scoops per day despite consuming it dry.

During the physical examination, it was observed that the young man appeared healthy but displayed facial expressions indicative of pain. His vitals were stable (blood pressure 114/71 mmHg, pulse of 58 beats/min, respiratory rate of 18 breaths/min, and a body mass index of 21.8 kg/m²). Systemic examination was unremarkable except for an S4 gallop during cardiac auscultation. His lipid profile was within acceptable range (low-density lipoprotein 1.02 mmol/L, high-density lipoprotein 1.53 mmol/L, triglycerides 0.77 mmol/L and total cholesterol 2.96 mmol/L). The electrocardiogram (ECG) showed sinus bradycardia with ST-segment elevation in the anterolateral leads (V2–V5, I, aVL) (Figure 1), and the transthoracic echocardiogram (ECHO) showed anterior wall hypokinesia with

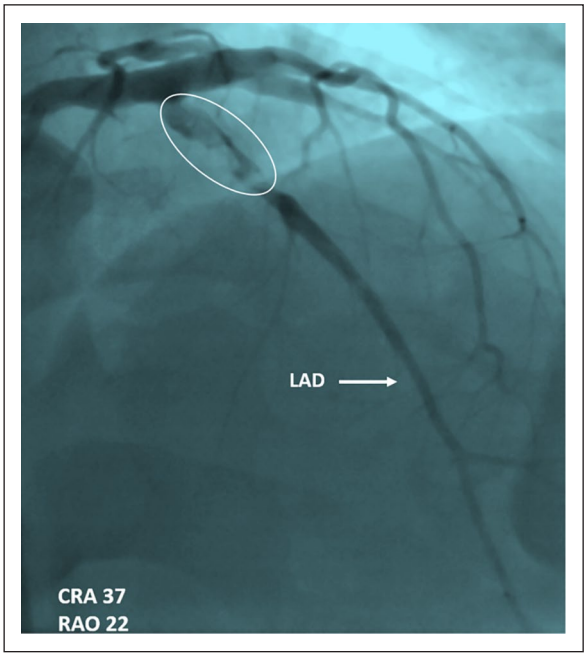

Figure 2. Coronary angiography-1 displaying a filling defect consistent with thrombosis, 100% occlusion of the proximal left anterior descending coronary artery artery, and distal tapering with TIMI 0 flow.

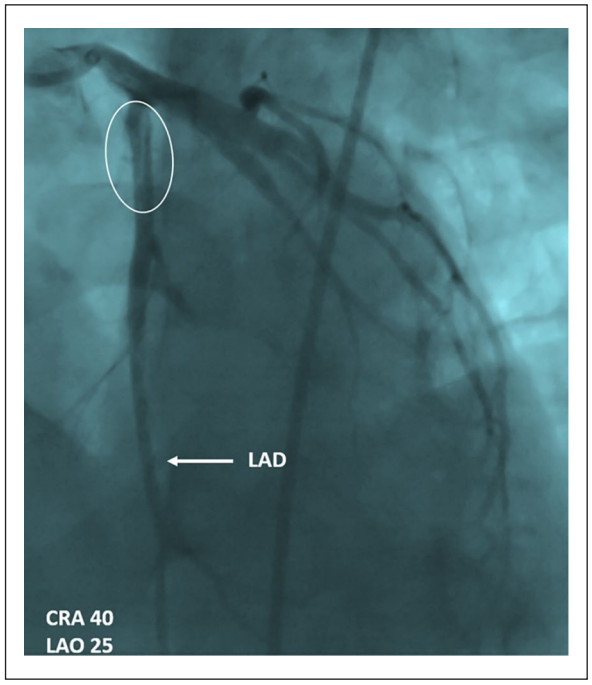

Figure 3. Coronary angiography-2 displaying a patent left anterior descending coronary artery vessel post revascularization with drug-eluting stent.

preserved global left ventricular systolic function (ejection fraction (EF) 68%). Laboratory evaluation (i.e., Prothrombin time, Partial thromboplastin time, D-dimer, Protein C, Protein S, Antithrombin III activity, and Factor VIII activity) did not indicate a hypercoagulable state or a systemic thromboembolic disease; however, cardiac enzymes were elevated, with a peak troponin I of 5.14 ng/mL and CK-MB of 78.1 ng/mL. Considering the above history and symptomatology, we entertained a diagnosis of anterolateral ST-elevation myocardial infarction. A loading dose of aspirin (300 mg), clopidogrel (600 mg), and atorvastatin (80 mg) were initiated, and the patient was taken for emergency coronary angiography.

Coronary angiography revealed a thrombotic lesion completely occluding the proximal left anterior descending coronary artery (LAD) with TIMI 0 flow distally (Figure 2). There was no evidence of atherosclerosis, dissection, or coronary malformations, and the right coronary system was intact. After successful balloon angioplasty, a drug-eluting stent (DES) was implanted successfully, restoring TIMI 3 flow to the proximal LAD (Figure 3). He remained free of chest pain during a 2-day observation in the coronary care unit, and a follow-up ECG showed resolution of ST-elevation. Following extensive counseling, he was discharged from the hospital with statin and dual antiplatelet therapy. Upon review 4 weeks later, he reported normal functional capacity, with neither chest pain nor ischemic changes on ECG (Figure 4). His follow-up ECHO revealed preserved EF with limited residual hypokinesia on the anterior wall.

Discussion

In this era of noncommunicable disease preponderance, individuals are increasingly becoming more health-conscious than before, with a vivid inclination toward fitness-oriented lifestyles. Parallel to this, there is a surging demand for pre-workout supplements (predominantly protein powder) from athletes and fitness enthusiasts, and the rapidly growing global sports nutrition market (valued at USD 45.24 billion in 2023) is projected to reach USD 77.95 billion by 2030.[27] Recent studies have revealed considerably high rates of pre-workout supplement consumption in fitness centers, ranging from 68.7% among Saudi women to 96% among gymnasium trainees in Lesotho.[28–35]

Designed to boost energy and augment athletic performance, protein formulas—largely containing a blend of performance-enhancing ingredients including caffeine, nitric oxide precursors (e.g., L-arginine, L-citrulline), creatine, beta-alanine, and branched-chain amino acids—are the most widely used formulations.[12,36] Typically sold in powder form, pre-workout supplements are recommended to be ingested with a liquid accompaniment (water or plant-based milk). Nevertheless, dry scooping, a rather risky act of consuming undiluted pre-workout powder hoping for a more pronounced energy surge, is increasingly becoming a fitness trend worldwide. Although it investigated an unorthodox platform (i.e., TikTok), a study by Lin et al. revealed that 86% of individuals portrayed improper use (including dry scooping) of pre-workout supplements.[37] Moreover, despite

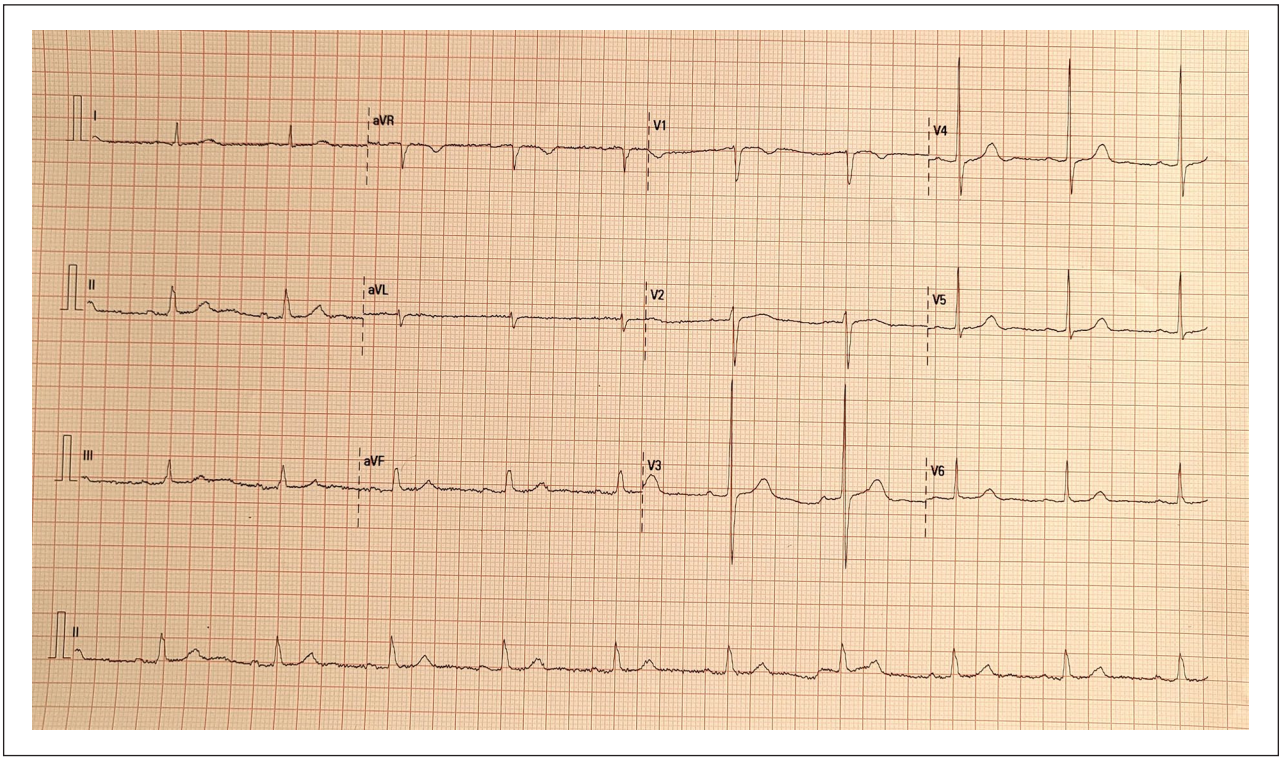

Figure 4. Electrocardiogram at follow-up displaying normal findings.

the purported benefits of dry scooping, ingestion of the highly concentrated powder could potentially lead to catastrophic symptoms ranging from choking to death.[37]

Similar to our earlier case on energy drinks and acute coronary syndrome,[38] this case report demonstrates a similarly life-threatening presentation in a young, healthy man with no obvious cardiovascular risk factors. Although the cause of coronary thrombus in our case remains uncertain, it is conceivable that the thrombus developed as a result of pre-workout-induced coronary spasm. As reiterated by previous articles,[23,39–43] some ingredients in pre-workout supplements (potentially synergistically) coupled with a catecholamine surge during exercise could potentially lead to spasm-induced thrombosis.[44,45] Furthermore, the current body of knowledge supports the notion of misinformed decisions and subsequently a wide variation in practice among pre-workout supplement users and prescribers.[46,47] Therefore, it is fundamental that athletes and fitness enthusiasts are aware of the potential risks linked to pre-workouts, particularly their improper use. Moreover, given the documented adverse health consequences following their improper use,[48–51] it is pivotal that pre-workout supplements are consumed as recommended.

Conclusion

Dry scooping, a practice not endorsed by health professionals or supplement manufacturers, carries life-threatening consequences. Given the potential risks associated with this improper method of consumption, it is pivotal for fitness enthusiasts to consume pre-workout supplements as directed to avoid the health repercussions of misuse. Additionally, ongoing research and monitoring are imperative to better understand the potential health consequences of pre-workout supplement use and to inform evidence-based recommendations for safe practices.

Acknowledgements

The authors are grateful to the patient for giving us the opportunity to learn and to pass on the lessons learnt to others.

Author contributions

P.P. and S.V.B. took the history and performed the physical examination. S.V.B. performed the cardiac imaging, and E.S.M. processed the laboratory investigations. Y.G. and P.R.K. performed the coronary angiography. S.V.B., P.P., J.M., P.R.K., M.K., and Z.S.M. participated in clinical management and counseling of the patient during hospitalization and follow-up. P.P. wrote the initial draft of the manuscript. All authors reviewed and contributed to the final version of this case report.

Declaration of conflicting interests

The author(s) declared no potential conflicts of interest with respect to the research, authorship, and/or publication of this article.

Funding

The author(s) received no financial support for the research, authorship, and/or publication of this article.

Ethics approval

Our institution does not require ethical approval for reporting individual cases or case series.

Informed consent

Written informed consent was obtained from the patients for their anonymized information to be published in this article.

ORCID iD

Pedro Pallangyo https://orcid.org/0000-0002-6720-5110

References

1. Anderson E and Durstine JL. Physical activity, exercise, and chronic diseases: a brief review. *Sports Med Health Sci* 2019; 1(1): 3–10.
2. Usmani D, Ganapathy K, Patel D, et al. The role of exercise in preventing chronic diseases: current evidence and recommendations. *Georgian Med News* 2023; 339: 137–142.
3. Saint-Maurice PF, Graubard BI, Troiano RP, et al. Estimated number of deaths prevented through increased physical activity among US adults. *JAMA Intern Med* 2022; 182(3): 349–352.
4. Aune D, Schlesinger S, Hamer M, et al. Physical activity and the risk of sudden cardiac death: a systematic review and meta-analysis of prospective studies. *BMC Cardiovasc Disord* 2020; 20: 318.
5. Guthold R, Stevens GA, Riley LM, et al. Worldwide trends in insufficient physical activity from 2001 to 2016: a pooled analysis of 358 population-based surveys with 1·9 million participants. *Lancet Glob Health* 2018; 6(10): e1077–e1086.
6. Varela AR, Cruz GIN, Hallal P, et al. Global, regional, and national trends and patterns in physical activity research since 1950: a systematic review. *Int J Behav Nutr Phys Act* 2021; 18: 5.
7. Fanous Y and Dorian P. The prevention and management of sudden cardiac arrest in athletes. *CMAJ* 2019; 191(28): E787–E791.
8. Corrado D, Basso C, Rizzoli G, et al. Does sports activity enhance the risk of sudden death in adolescents and young adults?. *J Am Coll Cardiol* 2003; 42: 1959–1963.
9. Corrado D, Basso C, Schiavon M, et al. Pre-participation screening of young competitive athletes for prevention of sudden cardiac death. *J Am Coll Cardiol* 2008; 52: 1981–1989.
10. Prakash K, Swarnakari K, Bai M, et al. Sudden cardiac arrest in athletes: a primary level of prevention. *Cureus* 2022; 14(10): e30517.
11. Wardenaar F, van den Dool R, Ceelen I, et al. Self-reported use and reasons among the general population for using sports nutrition products and dietary supplements. *Sports* 2016; 4(2): 33.
12. Harty PS, Zabriskie HA, Erickson JL, et al. Multi-ingredient pre-workout supplements, safety implications, and performance outcomes: a brief review. *J Int Soc Sports Nutr* 2018; 15(1): 41.
13. Hoffman JR, Faigenbaum AD, Ratamess NA, et al. Nutritional supplementation and anabolic steroid use in adolescents. *Med Sci Sports Exerc* 2008; 40: 15–24.
14. Froiland K, Koszewski W, Hingst J, et al. Nutritional supplement use among college athletes and their sources of information. *Int J Sport Nutr Exerc Metab* 2004; 14(1): 104–120.
15. Gallop A, Marx Bhagat C, et al. Psychosis in an 18-year-old male. *Contemp Pediatr* 2022; 39: 10.
16. Caratenuto R, Karanfilian B, Navlani R, et al. Social media trends, dry scooping, and extensive esophageal ulcerations. *J Gen Intern Med* 2023; 38(16): 3633–3635.
17. Bastola S, Kc O, Khanal S, et al. Hepatitis-associated aplastic anemia from workout supplement: rare but potentially fatal entity. *SAGE Open Med Case Rep* 2020; 8: 2050313X20901937.
18. Harris BF, Winn C and Ableman TB. Hemorrhagic stroke in a young healthy male following use of pre-workout supplement animal rage XL. *Mil Med* 2017; 182(9): e2030–e2033.
19. Magee CD, Moawad FJ and Moses F. NO-Xplode: a case of supplement-associated ischemic colitis. *Mil Med* 2010; 175(3): 202–205.
20. Ridha M, Rivera Gonzalez G and Seenivasagam M. Pre-workout-induced pancreatitis. *Cureus* 2023; 15(9): e44609.
21. Romick J, Viswanathan L and Ramos B. S2600 pre-workout peril: drug-induced liver injury in a young deployed service member. *Am J Gastroenterol* 2020; 115: S1365–S1366.
22. Doctorian T and Do B. Ascending aortic dissection in a young patient using a synephrine-containing workout supplement. *J Cardiol Cases* 2017; 15(5): 150–152.
23. Bonim A, Duarte SBCP, Dos Santos RB, et al. Acute myocardial infarction induced by pre-workout supplement in a young patient. *Open J Clin Med Case Rep* 2017; 3(10): 1259.
24. Karnatovskaia LV, Leoni JC and Freeman ML. Cardiac arrest in a 21-year-old man after ingestion of 1,3-DMAA-containing workout supplement. *Clin J Sport Med* 2015; 25(1): e23–e25.
25. Singer N and Lattman P. A workout booster, and a lawsuit. *The New York Times*, 13 February 2013, https://www.nytimes.com/2013/02/14/business/death-after-use-of-jack3d-shows-gap-in-regulation.html (accessed 12 March 2024).
26. Eudy AE, Gordon LL, Hockaday BC, et al. Efficacy and safety of ingredients found in pre workout supplements. *Am J Health Syst Pharm* 2013; 70: 577–588.
27. Grand View Research. Sports Nutrition Market Size, Share & Trends Analysis Report By Product Type (Sports Supplements, Sports Drinks), By Formulation, By Consumer Group, By Sales Channel, By Region, And Segment Forecasts, 2024–2030. https://www.grandviewresearch.com/industry-analysis/sports-nutritionmarket#:~:text=The%20global%20sports%20nutrition%20market,are%20essential%20for%20maximum%20performance.
28. Mazzilli M, Macaluso F, Zambelli S, et al. The use of dietary supplements in fitness practitioners: a cross-sectional observation study. *Int J Environ Res Public Health* 2021; 18(9): 5005.
29. Senekal M, Meltzer S, Horne A, et al. Dietary supplement use in younger and older men exercising at gyms in Cape Town. *S Afr J Clin Nutr* 2019: 1–8.
30. Aljebeli S, Albuhairan R, Ababtain N, et al. The prevalence and awareness of dietary supplement use among saudi women visiting fitness centers in Riyadh, Saudi Arabia. *Cureus* 2023; 15(6): e41031.
31. Solheim SA, Nordsborg NB, Ritz C, et al. Use of nutritional supplements by Danish elite athletes and fitness customers. *Scand J Med Sci Sports* 2017; 27: 801–808.
32. Morrison LJ, Gizis F and Shorter B. Prevalent use of dietary supplements among people who exercise at a commercial gym. *Int J Sport Nutr Exerc Metab* 2004; 14: 481–492.

33. da Silva WV, de Andrade Gomes Silva MI, Tavares Toscano L, et al. Supplementation prevalence and adverse effects in physical exercise practitioners. *Nutr Hosp* 2014; 29: 158–165.
34. Mettler S, Bosshard JV, Häring D, et al. High prevalence of supplement intake with a concomitant low information quality among Swiss Fitness Center users. *Nutrients* 2020; 12(9): 2595.
35. Sello MG, Letšoara M and Qhomoko M. The use of nutritional supplements among gymnasium trainees in Maseru, Lesotho. *World J Nutr Health* 2023; 11(1): 11–16.
36. Jagim AR, Harty PS and Camic CL. Common ingredient profiles of multi-ingredient pre-workout supplements. *Nutrients* 2019; 11(2): 254.
37. Lin A, Chow N, O'Connor M, et al. Dry scooping and other dangerous pre-workout consumption methods: a quantitative analysis. *Pediatrics* 2022; 149: 204.
38. Pallangyo P, Bhalia SV, Komba M, et al. Acute myocardial infarction following the consumption of energy drink in a 28-year-old male: a case report. *J Investig Med High Impact Case Rep* 2023; 11: 23247096231168811.
39. Suchard JR, Suchard MA and Steinfeldt JL. Physician knowledge of herbal toxicities and adverse herb-drug interactions. *Eur J Emerg Med* 2004; 11: 193–197.
40. Thomas JE, Munir JA, McIntyre PZ, et al. STEMI in a 24-year-old man after use of a synephrine-containing dietary supplement: a case report and review of the literature. *Tex Heart Inst J* 2009; 36(6): 586–590.
41. Smith TB, Staub BA, Natarajan GM, et al. Acute myocardial infarction associated with dietary supplements containing 1,3-dimethylamylamine and Citrus aurantium. *Tex Heart Inst J* 2014; 41(1): 70–72.
42. Haller CA and Benowitz NL. Adverse cardiovascular and central nervous system events associated with dietary supplements containing ephedra alkaloids. *N Engl J Med* 2000; 343(25): 1833–1838.
43. Samenuk D, Link MS, Homoud MK, et al. Adverse cardiovascular events temporally associated with ma huang, an herbal source of ephedrine. *Mayo Clin Proc* 2002; 77(1): 12–16.
44. Unnikrishnan D, Annam R, Jacob A, et al. STEMI in a young male after use of synephrine-containing dietary supplement. *Case Rep Cardiol* 2018; 2018: 7074104.
45. Johnson GJ, Griggs TR and Badimon L. The utility of animal models in the preclinical study of interventions to prevent human coronary artery restenosis: analysis and recommendations. *Thrombosis Haemostasis* 1999; 81(5): 835–843.
46. Jones G. Caffeine and other sympathomimetic stimulants: modes of action and effects on sports performance. *Essays Biochem* 2008; 44:109–123.
47. Kemper KJ, Gardiner P, Gobble J, et al. Expertise about herbs and dietary supplements among diverse health professionals. *BMC Complement Altern Med* 2006; 6: 15.
48. Schröder H, Navarro E, Mora J, et al. The type, amount, frequency and timing of dietary supplement use by elite players in the First Spanish Basketball League. *J Sports Sci* 2002; 20(4): 353–358.
49. Dunn MS, Eddy JM, Wang MQ, et al. The influence of significant others on attitudes, subjective norms and intentions regarding dietary supplement use among adolescent athletes. *Adolescence* 2001; 36(143): 583–591.
50. Cisek-Woźniak A, Mruczyk K and Wójciak RW. Physical activity and dietary supplementation intake among postmenopausal women. *Balt J Health Phys Act* 2019; 11(3): 66–76.
51. Deldicque L and Francaux M. Potential harmful effects of dietary supplements in sports medicine. *Curr Opin Clin Nutr Metab Care* 2016; 19(6): 439–445.